

The clinical economics of ultrasound-guided procedures

Katherine Slawsky, MPH^a, Michelle McInnis, MPA^a, Thomas F. Goss, PharmD^a, and David W. Lee, PhD^b

^aBoston Healthcare Associates, Boston, MA

^bGE Healthcare, Waukesha, WI

Introduction

Many physicians use landmark (or “blind”) techniques to perform needle-related procedures at the point of care, such as line placements, aspirations, injections, or other interventions. Because landmark techniques do not account for human anatomical variation or enable the physician to see the area of interest, they can increase the number of attempts, as well as the risk of complications and sub-optimal outcomes.

With ultrasound, physicians have a real-time visual assistant to help them quickly, safely, and precisely guide procedures in the office or at the bedside. Using ultrasound, physicians can see beneath the skin’s surface to make immediate care decisions and avoid complications. In some cases, this added information can completely change the course of action or treatment for a patient. Ultimately, the ability to improve outcomes, reduce risk, and control costs can change the bottom line for the healthcare system and the overall experience for the patient.

Background and methods

An abundance of studies and peer-reviewed papers articulate how ultrasound guidance is greatly improving clinical outcomes across many applications. Less well understood, however, is the economic impact this has on healthcare. The clinical efficacy of ultrasound guidance can be translated into significant cost savings in several ways, including reduction of procedure-related complications and cost, shorter procedure times, reduced hospital length-of-stay, increased use of minimally-invasive procedures in less expensive outpatient settings, and more consistent success across a broader range of qualified physicians, residents, and nurses.

The goal of improving clinical outcomes and the overall health of patients is paramount for all providers, but doing so in a

cost-conscious way is important as well. As healthcare organizations cope with constrained resources, reduced budgets, pay-for-performance pressures, and capacity issues, ultrasound guidance has the potential to play an important role in making quality care more affordable and less costly for millions of patients and their providers.

This paper summarizes the published economic evidence comparing ultrasound-guided procedures with current standards of care in order to better understand the potential cost savings, benefits, and value of ultrasound-guided procedures.

A structured literature review was conducted in both the National Library of Medicine’s PubMed database and the Cochrane Library to identify relevant articles (between January, 2000, and August, 2009). Articles were considered to be relevant if they reported the costs, resources, and/or efficacy of ultrasound-guided procedures as compared with current standard of care for the procedure. Reference lists from retrieved articles were checked to ensure robustness and fair balance of the literature search.

Specifically, this paper addresses four key areas in which the clinical and cost-savings advantages of ultrasound guidance are emerging most strongly:

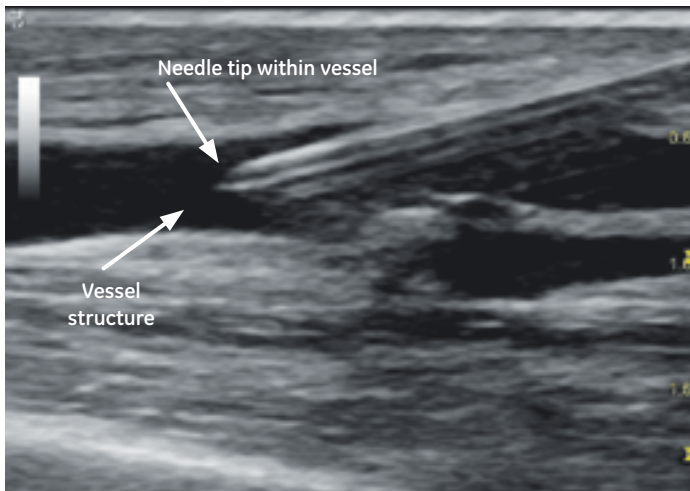
- Vascular access
- Aspirations
- Nerve block and therapeutic injections
- Minimally invasive procedures

In each section, we present a summary of relevant research findings, comparisons of ultrasound-guided procedures with current standards of care, and the potential for financial and value impact.

Vascular access: realizing the savings of safety

Vascular access is necessary for a variety of purposes across clinical settings, including venous access to allow for hemodialysis, parenteral nutritional support, and delivery of medications.¹ Landmark guidance (catheter insertion based on anatomical landmarks, palpation, and static ultrasound location followed by insertion without dynamic guidance) has been the mainstay of initiating vascular access for decades. This technique, however, depends heavily on detailed knowledge of vascular anatomy and significant clinical experience in order to optimize successful catheter placement and minimize complications.

Alternatively, the use of ultrasound in guiding catheter insertion for central venous access has been advocated by the United States Agency for Healthcare Research and Quality (AHRQ) as one of the top 11 means of increasing patient safety in the United States.²



AHRQ recommends the use of ultrasound to clearly visualize the needle and vessel for vascular access, for improved safety and reduced number of attempts.

Many recent studies have examined the use of ultrasound guidance in placement of catheter lines for vascular access and reported improved success rates and decreased incidence of associated adverse events such as arterial puncture, hematoma, and pneumothorax (Table 1). There are approximately 3 million to 5 million central lines placed annually in the United States.³ Due to the sheer volume, even rare complications are likely to be experienced by most operators at some point. Thus, prevention of such complications becomes a critical tool for cost control efforts.

Ultrasound guidance for venous cannulation consistently results in higher rates of success with lower incidence of complications, particularly for users less experienced in landmark methods. The outcome gap between experienced and inexperienced operators narrows or becomes nonexistent with the use of ultrasound guidance, allowing a broader spectrum of trained users to successfully cannulate patients requiring venous access.^{4,5} With ultrasound guidance, more consistent success across more operators may result in substantial reductions in costs associated with procedure-related complications (Figure 1).

A meta-analysis published in 2003 examined 18 randomized, controlled trials of central venous catheterization.⁶ All studies compared ultrasound-guided placement to landmark methods, and procedures were performed by a variety of operators including residents, anesthesiologists, nephrologists, and emergency and intensive care physicians. Overall, the analysis demonstrated clear clinical benefits from ultrasound guidance as compared to traditional landmark methods, made evident by its association with an increased number of successful first attempts and catheterizations alongside reductions in complications, cannulation attempts, and time in achieving successful placements.

A study examining the effects of implementation of ultrasound guidance for central venous catheter (CVC) placement in the UK reported that complication rates dropped from 10.5% with landmark methods to 4.6% with

Table 1.
Reducing risk with ultrasound guidance of central vein catheter insertion⁸

Study setting and population	Intervention	Relative risk reduction (%)		
		Failed catheter insertion	Mean insertion attempts required	Complications
Tertiary care, teaching hospital ICU ⁹	IJV CVC insertion	100*	44	N/A
Tertiary care, teaching hospital, cardiothoracic surgical patients ¹⁰	IJV CVC insertion	100	44	83*
Tertiary care, teaching hospital, cardiac patients ¹¹	IJV cardiac catheterization and CVC insertion	100	48	80
Urban teaching hospital ICU ¹²	SCV CVC insertion	86	48	90
Urban teaching hospital emergency department, during CPR ¹³	FV CVC insertion	71	54	100

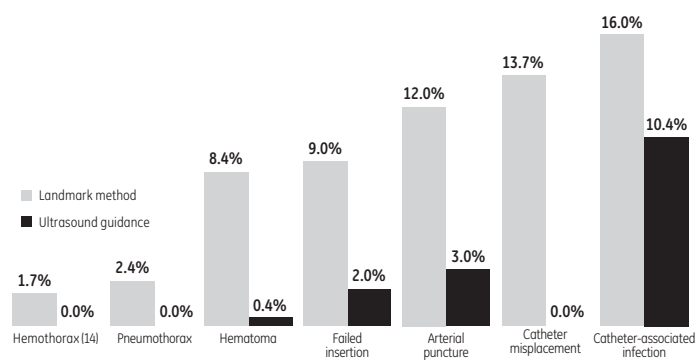
According to several prospective, randomized trials, using ultrasound to place catheters in the internal jugular vein has been associated with fewer failed insertions, improved first-pass success, and a reduction in complications. These clinical advantages can translate into economic savings by lowering the costs associated with treating complications and increasing the efficiency of care.

ICU, intensive care unit; IJV, internal jugular vein; CVC, central venous catheter; SCV, subclavian vein; FV, femoral vein; CPR, cardiopulmonary resuscitation.

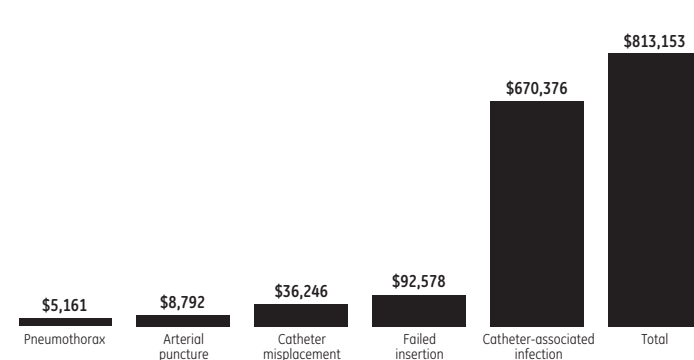
*Not statistically significant.

Figure 1.

Complications associated with IV catheterization are reduced with the use of ultrasound*



Estimated cost savings per 1,000 patients with ultrasound-guided IV catheterization*



Compared with the landmark method of IV catheterization, ultrasound-guided catheter insertion is associated with significantly lower complication rates and associated cost-savings. The studies cited here suggest a potential cost reduction per 1,000 patients ranging between 22% and 100%.

*Meant to be illustrative only. See notes section for the derivation of these figures.

ultrasound guidance, respectively—an absolute risk reduction of 5.9% and a relative risk reduction of 44%.⁷ Further, a prospective comparison between ultrasound-guided and landmark internal jugular vein (IJV) catheterization found significant reduction in rates of hematoma (0.4% vs. 8.4%, $p < 0.001$), hemothorax (0% vs. 1.7%, $p < 0.001$), and pneumothorax (0% vs. 2.4%, $p < 0.001$), favoring ultrasound guidance.¹⁴

The clinical advantages of ultrasound-guided venous access have been reported to translate into economic savings, reducing costs associated with treating complications.

A 2009 economic evaluation reported the annual cost of pneumothorax resulting from landmark-guided central line placement in the United States at approximately \$5 million–\$10 million, assuming a conservative 1.5% rate of pneumothorax at an incremental cost of \$134.49 per patient to treat.³ This is likely to be a conservative estimate; in 2003, Boland, et al. evaluated the cost-effectiveness of Hickman line insertion by nurses and estimated a cost of \$598.19 (£316.02) for pneumothorax, the cost estimate utilized by the National Institute for Clinical Excellence (NICE) in its evaluations.¹⁵ In addition, the Boland study estimated that the cost of repositioning a misplaced catheter tip ranged from \$73.09–\$456.05* per procedure. In Hickman line insertion, the cost of a failed insertion, which resulted in an alternative method of vascular access such as peripherally inserted central catheter (PICC) line placement, ranged from \$95.09–\$2,550.01.† Given that these complications are reported at rates of or near 0% with the use of ultrasound guidance, overall potential cost savings with ultrasound guidance are substantial.

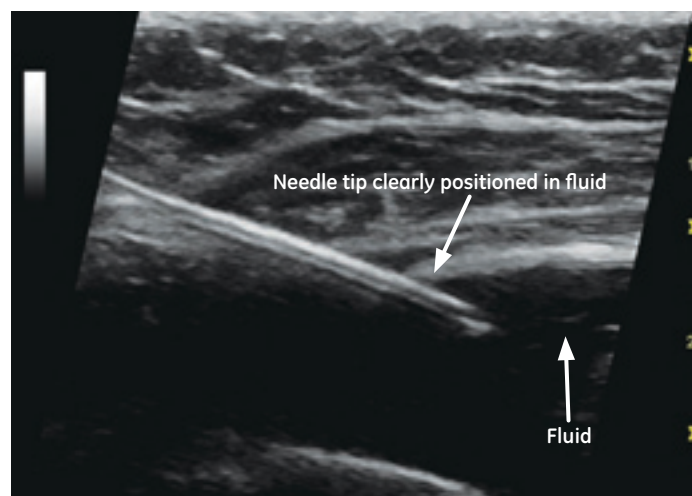
In conclusion, reductions in needle passes and failure rates can mean fewer repeat procedures, improved patient experience, and greater clinician efficiency. Also, lower complication rates in patients requiring vascular access mean less money spent managing adverse effects. Furthermore, success rates are virtually equal across all

operators—from residents to nurses to experienced physicians—which means a broader spectrum of qualified medical professionals who can safely and effectively complete the procedure.

Aspirations: preventing the cost of complications

Aspiration procedures are performed across a variety of settings, including joint aspiration, aspiration of wound abscesses, and additional aspiration procedures, such as thoracentesis, pericardiocentesis, and paracentesis. Ultrasound-guided aspiration is significantly more successful than aspiration procedures relying on traditional landmark methods, and is associated with reduction in procedure-related complications and their associated costs.

Greater success rates with ultrasound-guided aspiration may result in fewer follow-up visits and compensatory procedures, delivering cost savings.



Ultrasound guidance helps improve accuracy of needle placement for fluid aspiration, which is crucial for procedure success and complication avoidance.

*Converted from £50.98-£318.07; <http://www.xe.com/ucc/>; 8/24/09.

†Converted from £66.33-£1,778.69; <http://www.xe.com/ucc/>; 8/24/09.

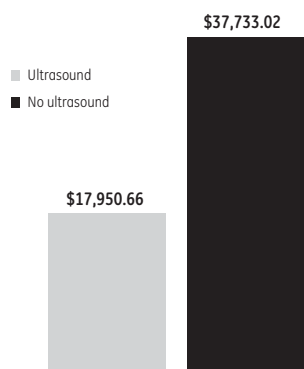
For example, the aspiration of joint effusions and soft tissue fluid collection is a routine diagnostic and therapeutic procedure in clinical rheumatology. Accurate needle placement is crucial to procedure success; however, several studies examining needle placement using landmark methods have reported success rates as low as 32% in tendon sheath injections and 42% in glenohumeral joint injections.¹⁸

A prospective study comparing ultrasound-guided aspiration of joint and soft tissue fluids to aspirations performed by rheumatologists using landmark methods reported success rates of 97% in the ultrasound guidance group as compared with 32% in patients whose needles were placed blindly.¹⁸

In pediatrics, standard management of children presenting with irritable hip has been hospitalization and observation for four to seven days in order to distinguish sepsis, which would require immediate treatment, from transient synovitis.¹⁹ Ultrasound-guided aspiration of the hip joint allows physicians to obtain synovial fluid and run an immediate Gram stain to determine the presence or absence of infection, thus alleviating the need for hospital admission. In one prospective study, 36 pediatric hip aspirations resulted in only two hospitalizations, demonstrating significant reduction in hospital resource use associated with long admissions for observation.¹⁹

Thoracentesis performed with ultrasound guidance results in significant reductions in costly post-procedure complications such as pneumothorax, reducing the overall costs associated with the procedure.^{20,21} A review of medical records of 450 thoracentesis procedures found that ultrasound guidance reduced the rate of pneumothorax by more than half (10.3% vs. 4.9%, $p < 0.05$).²² Given that the estimated cost of treating pneumothorax ranges from \$134.49–\$598.19, this reduction in complications has significant economic implications³ (Figure 2).

Figure 2. Estimated cost of pneumothorax per 1,000 thoracentesis procedures*



Thoracentesis performed with ultrasound guidance has been shown to reduce post-procedure complications, such as pneumothorax, resulting in significant cost savings.

*Meant to be illustrative only. See notes section for the derivation of these figures.

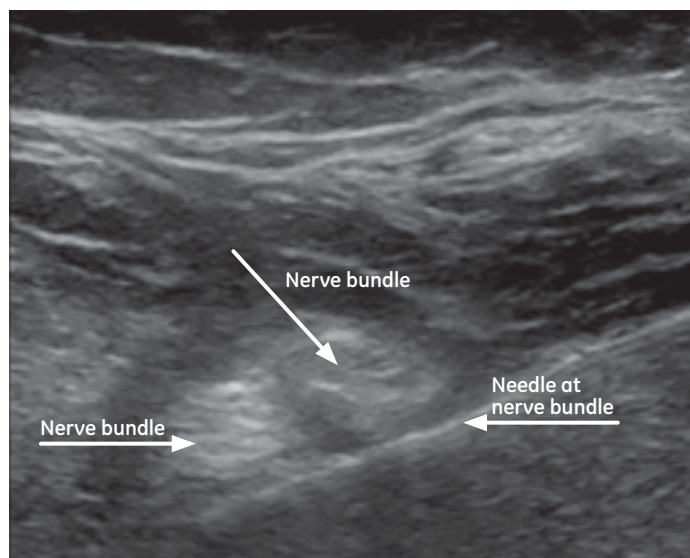
Ultrasound diagnosis and guidance in patients recommended for paracentesis not only increases procedure success, but also helps eliminate the need for unnecessary procedures in certain patients in whom no or insignificant ascites is detected upon examination.

In patients with suspected ascites, paracentesis is often indicated though not always necessary. In one study, 100 patients were prospectively randomized to receive paracentesis using traditional (n=44) or ultrasound-guided techniques (n=56).²³ In patients receiving paracentesis with traditional methods, 61% of the procedures were successful. Of the patients whose procedures were performed using ultrasound guidance, paracentesis was found to be unnecessary in 25%. In the patients who did complete the more invasive procedure, 95% were aspirated successfully with ultrasound guidance.

In conclusion, ultrasound-guided aspiration helps reduce procedure-related complications compared with landmark methods, resulting in higher success rates and reduced costs. Ultrasound guidance may even eliminate the need for paracentesis in some patients.

Nerve block and therapeutic injections: saving time through accuracy and improved performance

Ultrasound needle guidance increases the rate of accurate placement of injections for interventional procedures, such as nerve blocks for regional anesthesia, as well as corticosteroid injections and needle tenotomy procedures commonly used in sports medicine, orthopedics, and pain management practices. Ultrasound also allows real-time visualization of diffusion of the injectable, such as anesthetic spread around the nerve, to confirm accurate delivery and efficacy of the product.²⁴



Visualization of the nerve and needle with ultrasound can help improve block success and performance while reducing complication rates.

Image courtesy of Brian A. Pollard, MD. An Introductory Curriculum for Ultrasound-Guided Regional Anesthesia. A Learner's Guide. 2009. UTPRIN, Pollard BA, Chan VW. Division of University of Toronto Press Inc. www.usra.com

Table 2.

Improvements with ultrasound-guided peripheral nerve blocks³⁰

Outcome	Block type	Ultrasound	Nerve stimulation	P-value
Performance (minutes)	Supraclavicular	5.0 +/- 2.4	9.8 +/- 7.5	<0.001 ²⁶
Onset (minutes)	Supraclavicular	9 (range 5–15)	15 (range 5–25)	<0.001 ³¹
	Three-in-one	16 +/- 14	27 +/- 16	<0.05 ³²
	Three-in-one	13 +/- 16	27 +/- 12	<0.01 ³³
Duration (minutes)	Supraclavicular	384 (range 280–480)	310 (range 210–420)	<0.001 ³¹

By enabling real-time visualization of peripheral nerves, needle, and the spread of the local anesthetic injection, ultrasound has been shown to increase the speed of onset and duration of peripheral nerve blocks, which may reduce costly operating room time.

One prospective randomized study reported a 76.6% success rate on first attempt in lateral midfemoral sciatic nerve block with ultrasound guidance as compared with only 41.9% success in procedures performed using nerve stimulation alone ($p < 0.01$).²⁴ After multiple attempts, 22% of the patients in the nerve stimulation group still had not achieved a complete sensory block and required general anesthesia for surgery. In other words, longer time was taken to perform multiple regional block attempts with nerve stimulation, and still nearly one-quarter of the patients required general anesthesia, adding significant time and overall resource utilization to the procedure. In one cost model, ultrasound-guided nerve blocks were reported to be cost competitive with nerve stimulation in ambulatory settings; ultrasound guidance was associated with lower costs unless the accuracy of nerve stimulation was at least 96%.²⁵

Ultrasound-guided injections also have the potential to decrease procedure time and related complications as well as increase speed of onset and duration of sensory and motor block (Table 2, Figure 3). One randomized clinical trial reported mean time to supraclavicular nerve block of five minutes with ultrasound guidance as compared with 9.8 minutes using nerve stimulation.²⁶ Another study reported that surgical procedures could proceed 15 minutes earlier when axillary nerve blocks were performed with ultrasound guidance as compared to nerve stimulation, thereby reducing operating room time.²⁷ Ultrasound-guided nerve block also has demonstrated efficacy when performed by medical residents. In a retrospective study of resident-performed

blocks, 99.3% were blocked successfully, without the need for a (ultrasound) specialist.²⁸

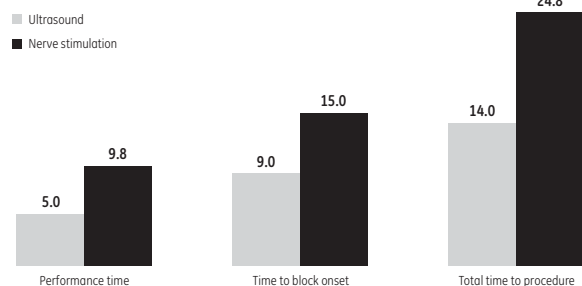
In addition to clinical factors and the potential reduction in surgical specialist and operating room time, ultrasound-guided regional blocks have been shown to reduce related complications—another benefit with potentially significant economic implications. The reported incidence of minor complications, such as arterial puncture, is significantly lower in ultrasound-guided injections as compared with nerve stimulation. One prospective study reported a 3.2% incidence of arterial puncture with ultrasound guidance as compared with 9.7% for nerve stimulation ($p = 0.03$).²⁹

The placement accuracy of ultrasound-guided injections has been demonstrated to improve patient outcomes. A 2004 study compared ultrasound-guided corticosteroid injection to landmark methods of injection for patients with painful shoulder. The study reported significant increases in patient satisfaction as measured by a visual analog scale for pain (VAS) and the Shoulder Function Assessment (SFA) in patients receiving ultrasound-guided injections. Six weeks after injection, the mean VAS score improvement from baseline was 34.9 in ultrasound-guided patients as compared with only 7.1 in patients who were injected using landmark techniques ($p < 0.001$). Mean SFA score changes were 15 and 5.6 for ultrasound guidance versus landmark, respectively ($p = 0.012$).³⁴

Increased success rates of intra-articular injections also have been reported with ultrasound guidance. One randomized controlled study reported that relative to conventional palpation-guided methods, ultrasound guidance resulted in a 43% reduction in procedural pain and a 25.6% increase in responder rate.³⁵ While the majority of studies examining ultrasound-guided injection report failure rates of less than 10%, inaccurate needle placement with palpation guidance have been reported at 12%–70% in subacromial bursa, 58%–75% in the glenohumeral joint, and 15%–30% in the knee.³⁵ The lower failure rates associated with ultrasound-guided procedures may translate into fewer follow-up visits and repeat procedures associated with injection failure.

Ultrasound guidance for some injections is as effective as more expensive methods of image guidance, such as fluoroscopy and CT imaging.

Figure 3. Time to nerve block (minutes)*



Ultrasound guidance for nerve block injections has been shown to significantly increase speed of onset and reduce overall procedure time.

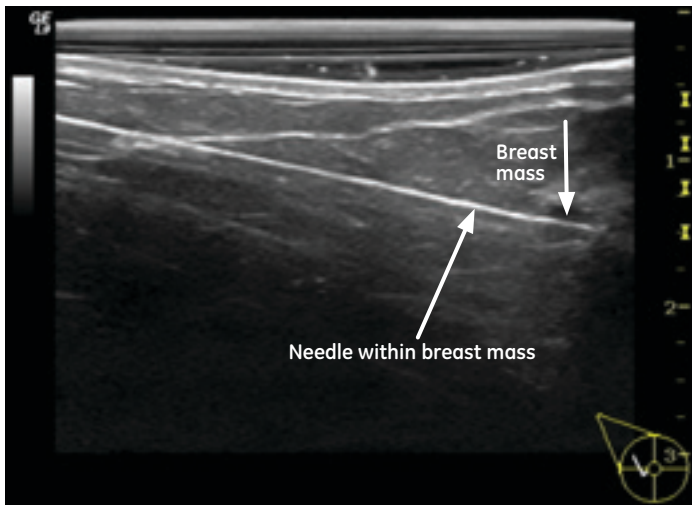
*Meant to be illustrative only. See notes section for the derivation of these figures.

In rheumatology injections such as intra-articular hyaluronic acid injections for hip osteoarthritis, ultrasound-guided injections have been shown to be as effective as both fluoroscopy and CT.^{36,37} Ultrasound guidance in these instances not only replaces more expensive procedures, but also avoids exposing the patient to radiation.

In conclusion, patients with more effective pain management are less likely to require additional follow-up visits and procedures, potentially reducing overall resource utilization. Ultrasound guidance has shown to be far more sensitive and accurate than landmark or nerve stimulation techniques for injections. By reducing the time to perform nerve blocks, ultrasound guidance enables faster procedures and operating room turnover. For therapeutic injections, the increased accuracy of ultrasound guidance can mean fewer repeat procedures.

Minimally invasive procedures: reducing the complexity and cost of surgery

Ultrasound guidance is enabling a critical transition in patient care as more invasive surgical procedures traditionally requiring hospital admission are now possible using minimally invasive outpatient procedures. This not only decreases patient surgical burden and recovery time, but also reduces the resources necessary to care for the patient during and after the procedure.



Minimally invasive procedures like ultrasound-guided breast biopsy can replace invasive and more costly procedures.

Biopsy/Fine Needle Aspiration (FNA)

Tumor biopsy is a routine procedure in the diagnosis and treatment of various tumors and cancers. Staging and histological diagnosis are crucial to treatment decisions, and this is often accomplished through surgical or cutting needle biopsy. These techniques are invasive and result in increased complication rates. Reported overall rates of complications in cutting needle biopsy have been as high as 4%, while fine-needle aspiration (FNA) very rarely results in complications, with complication rates reported

between 0.187% and 0.55%. Specifically, reported rates of pneumothorax resulting from CT- and fluoroscopy-guided biopsies vary from 8–61%, while the complication rates using ultrasound-guided biopsy are reported to be approximately 4%.³⁸

By reducing the need for open surgical biopsy and subsequent hospitalization, ultrasound guidance can lower the costs associated with follow-up imaging, clinical visits, and surgical complications.

In breast cancer patients, preoperative ultrasound and FNA of the axilla resulted in an 8–14% reduction in the rate of sentinel lymph node procedures subsequently performed.^{39,40} Additionally, vacuum-assisted ultrasound-guided excision biopsies can be performed as outpatient procedures for diagnosis and treatment of breast fibroadenomas.⁴¹ Vacuum-assisted biopsies are associated with infrequent complications, the most commonly reported adverse event being mild postoperative pain.⁴² In such instances, patients who otherwise would have undergone open surgical biopsy or excision can be treated with a minimally invasive outpatient procedure.

One cost-effectiveness study comparing palpation-guided thyroid fine needle aspiration (P-FNA) to ultrasound-guided fine needle aspiration (USG-FNA) reported that universal application of USG-FNA for all thyroid nodules is cost-effective and results in savings of \$203.52* per additional accurate diagnosis of benign versus malignant thyroid nodular disease.⁴³

Vein care

Ultrasound guidance has numerous applications in vascular surgery. Varicose veins, for example, are a common condition estimated to affect up to 25% of adults.⁴⁴ Treatment has traditionally involved surgical ligation and stripping, performed as an in-hospital day procedure under general anesthesia and associated with a painful recovery process. Newer minimally invasive techniques that utilize ultrasound guidance such as foam sclerotherapy injection, radiofrequency (RF) ablation, and endovenous laser therapy (EVLT) have demonstrated increased clinical efficacy and patient satisfaction as well as reductions in procedure time and a shift from hospital-based to outpatient procedures.

In a randomized trial of patients being treated for varicose veins, costs were nearly 40% less for ultrasound-guided sclerotherapy compared with surgical ligation and stripping.⁴⁵

Ultrasound guidance for injection of foam sclerotherapy has been reported to be clinically and economically superior to surgical treatment of varicose veins. One randomized trial reported that time taken to complete the procedure was significantly shorter with ultrasound-guided foam sclerotherapy with sapheno-femoral ligation as compared with surgical ligation and stripping (median 45 minutes vs. 85 minutes, $p < 0.001$). While complications were infrequent

in both groups, the median time to return to normal activity was only two days in the ultrasound-guided group (range 0-6), as compared with eight days (range 5-20) in the surgical group ($p < 0.001$).⁴⁵

RF ablation has shown similar advantages over surgical stripping and ligation. In one prospective randomized study, 80.5% of patients receiving RF ablation returned to routine activities of daily living within one day, compared with 46.9% of patients treated surgically ($p < .01$).⁴⁶ Additionally, patients were able to return to work approximately 4.7 days post-procedure with RF ablation. In contrast, return to work took an average of 12.4 days for patients treated surgically ($p < 0.05$).

Ultrasound-guided alternatives to invasive surgical stripping and ligation can be associated with substantially lower rates of deep vein thrombosis, indicating an opportunity for significant economic savings.

Deep vein thrombosis (DVT), while rare, is a severe complication associated with varicose vein therapy. One study of surgical repair of varicose veins reported an incidence of DVT of 5.3%.⁴⁷ While few studies have directly compared vein care techniques, DVT rates of 0.3% and 2.7% have been reported for EVLT and RF ablation, respectively.⁴⁸ One article examining direct medical costs associated with DVT management reported that mean six-month costs for inpatient management ranged from \$3,906 to \$17,168, depending on the occurrence of additional serious complications such as pulmonary embolus.⁴⁹ When managed in an outpatient setting, costs of DVT ranged from \$2,394 to \$3,369. Despite the low incidence of DVT as a complication of varicose vein therapy, ultrasound guidance has the potential for significant economic impact by helping to lower the rate of DVT occurrence (Figure 4).

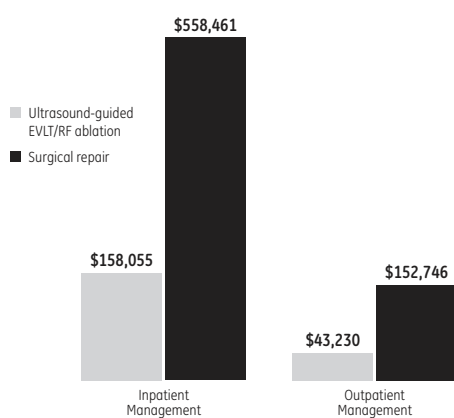
In conclusion, by using ultrasound guidance, many procedures traditionally performed with invasive surgeries can be successfully completed with minimally invasive techniques. In addition, ultrasound-guided techniques can result in fewer complications compared with more invasive surgeries and allow many procedures to now be performed on an outpatient basis, reducing overall cost and resource utilization.

Conclusion

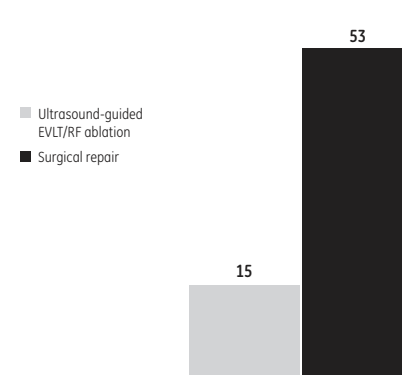
Ultrasound guidance can mean lower cost, better quality, and greater access through technology that has widespread application across various care settings, physician types, and clinical procedures (Table 3). Ultrasound has the ability to provide real-time visualization in areas such as vein cannulation, injection, and aspiration, and has enabled the development of new minimally invasive procedures that reduce the need for more invasive and expensive surgeries. Recent advancements in ultrasound's ease of use and portability also allow procedures to be performed by a wide scope of healthcare practitioners, giving patients faster access to improved clinical care.

Across all applications, evidence is accumulating for the clinical and economic advantages of ultrasound-guided interventions. The avoidance of common and costly adverse events, invasive techniques, and additional procedures can result in significant cost-savings to the healthcare system, whether at a hospital, outpatient clinic, or physician office. Consequently, the implementation of ultrasound guidance can help meet the goals of various stakeholders who want to remain resource-conscious, while achieving the ultimate goal of overall health improvement for patients.

Figure 4.
Estimated cost of deep vein thrombosis per 1,000 varicose vein procedures*



Estimated number of deep vein thrombosis per 1,000 varicose vein procedures



Ultrasound guidance has the potential for significant economic impact by helping to lower the rate of deep vein thrombosis.

*Meant to be illustrative only. See notes section for the derivation of these figures.

Table 3.

Ultrasound-guided application by specialty

Specialty	Examples of ultrasound-guided applications	Vascular access	Aspirations	Injections	Minimally invasive procedures
Anesthesiology	Central venous cannulation, local and regional nerve block	✓		✓	
Breast surgery	Cyst aspiration, FNA, core needle biopsy		✓		✓
Cardiology	Heart catheterization, surgery for aortic valve stenosis, percutaneous septal ablation, percutaneous cardiac interventions, atrioventricular valve repair, cardiac tamponade, transcatheterballoon valvuloplasty, transeptal puncture and radiofrequency ablation for arrhythmias		✓		✓
Emergency/ Critical care	Central venous catheter placement, inferior vena cava filters, thoracentesis, paracentesis, pericardiocentesis, nasogastric tube placement, percutaneous feeding enterostomies, nerve blocks	✓	✓	✓	✓
Endocrinology	FNA of thyroid nodules		✓		✓
ENT/ Otolaryngology	Percutaneous ethanol thyroid ablation, FNA, core needle biopsy of parotid glands, biopsy and aspiration of head and neck lesions, lithotripsy of salivary calculi		✓		✓
Nursing	PICC line placement, Hickman insertion	✓			
Obstetrics and Gynecology (OB/GYN)	Uterine artery embolization, amniocentesis, placement of cervical cerclage, cordocentesis/PUBS, CVS, embryo transfer, sonohysterosalpingography		✓		✓
Oncology	Radiofrequency ablation, radiation therapy, thermal ablation, cryoablation, radioactive seed implantation, biopsy, FNA	✓	✓		✓
Orthopedic surgery	Continuous interscalene brachial plexus catheter, percutaneous surgery, peripheral nerve block, hip arthrocentesis, femoral nerve block	✓	✓	✓	✓
Pain management	Cryoanalgesia, nerve blocks of the cervical and lumbar joints, stellate ganglion block, intercostal nerve blocks, peripheral nerve blocks, blocks of painful stump neuromas, caudal epidural injections, chemical neurolysis	✓		✓	
Physiatry	Neuromuscular block, corticosteroid injection, neurotomy, carpal tunnel injections, percutaneous needle tenotomy, piriformis injection			✓	
Radiology/ Interventional radiology	Thoracentesis, paracentesis, abscess drainage, percutaneous cholecystectomy, inferior ven cava filter placement, central venous catheter placement, PICC placement, cyst drainage, biopsy, ETOH liver injections, radioactive seed placement, thrombin injections, renal biopsies, FNA breast/thyroid, TIPS placement	✓	✓	✓	✓
Rheumatology	Injection for synovitis, tendonitis, tenosynovitis, enthesitis, bursitis, aspiration/drainage		✓	✓	
Sports medicine	Carpal tunnel injections, corticosteroid injections, percutaneous needle tenotomy, tendon surgery, sclerosing polidocanol injections			✓	
Vascular surgery	Venous ablation, vascular access	✓			✓

References

1. Maecken T, Grau T. Ultrasound imaging in vascular access. *Crit Care Med* 2007; 35(5 Suppl):S178-S185.
2. Agency for Health Care Research and Quality (AHRQ). Evidence Report/Technology Assessment: Number 43. Making Health Care Safer. A Critical Analysis of Patient Safety Practices: Summary 2001.
3. Kinsella S, Young N. Ultrasound-Guided Central Line Placement as Compared with Standard Landmark Technique: Some Unpleasant Arithmetic for the Economics of Medical Innovation. *Value in Health* 2009; 12(1):98-100.
4. Geddes CC, et al. Insertion of internal jugular temporary hemodialysis cannulae by direct ultrasound guidance – a prospective comparison of experienced and inexperienced operators. *Clin Nephrol* 1998; 50(5):320-325.
5. Kusminsky RE. Complications of central venous catheterization. *J Am Coll Surg* 2007; 204(4):681-696.
6. Hind D, et al. Ultrasonic locating devices for central venous cannulation: meta-analysis. *BMJ* 2003; 327(7411):361.
7. Wigmore TJ, Smythe JF, Hacking MB, Raobaikady R, MacCallum NS. Effect of the implementation of NICE guidelines for ultrasound guidance on the complication rates associated with central venous catheter placement in patients presenting for routine surgery in a tertiary referral centre. *Br J Anaesth*. 2007 Nov; 99(5): 662-5. Epub 2007 Sep 14.
8. Rothschild JM. Ultrasound guidance of central vein catheterization. In: *On making health care safer: a critical analysis of patient safety practices*. Rockville, MD: AHRQ Publications, 2001; Chapter 21:245–55.
9. Mallory DL, et al. Ultrasound guidance improves the success rate of internal jugular vein cannulation. A prospective, randomized trial. *Chest* 1990; 98(1):157-160.
10. Troianos CA, Jobes DR, Ellison N. Ultrasound-guided cannulation of the internal jugular vein. A prospective, randomized study. *Anesth Analg* 1991; 72(6):823-826.
11. Denys BG, Uretsky BF, Reddy PS. Ultrasound-assisted cannulation of the internal jugular vein. A prospective comparison to the external landmark-guided technique. *Circulation* 1993; 87(5):1557-1562.
12. Gualtieri E, Deppe SA, Sipperly ME, Thompson DR. Subclavian venous catheterization: greater success rate for less experienced operators using ultrasound guidance. *Crit Care Med* 1995; 23(4):692-697.
13. Hilty WM, Hudson PA, Levitt MA, Hall JB. Real-time ultrasound-guided femoral vein catheterization during cardiopulmonary resuscitation. *Ann Emerg Med* 1997; 29(3):331-336.
14. Karakitsos D, et al. Real-time ultrasound-guided catheterization of the internal jugular vein: a prospective comparison with the landmark technique in critical care patients. *Critical Care* 2006; 10(6):R162.
15. Boland A, Haycox A, Bagust A, Fitzsimmons L. A randomised controlled trial to evaluate the clinical and cost-effectiveness of Hickman line insertions in adult cancer patients by nurses. *Health Technology Assessment* 2003; 7(36):iii, ix-x,1-99.
16. Calvert N, et al. Ultrasound for central venous cannulation: economic evaluation of cost-effectiveness. *Anaesthesia* 2004; 59(11):1116-1120.
17. Warren DK, et al. Attributable cost of catheter-associated bloodstream infections among intensive care patients in a nonteaching hospital. *Crit Care Med*. 2006; 34(8):2084-9.
18. Balint PV, et al. Ultrasound guided versus conventional joint and soft tissue fluid aspiration in rheumatology practice: a pilot study. *J Rheumatol* 2002; 29(10):2209-2213.
19. Fink M, Berman L, Edwards D, Jacobson SK. The irritable hip: immediate ultrasound guided aspiration and prevention of hospital admission. *Archives of Disease in Childhood* 1995; 72(2): 110-113.
20. Jones PW, Moyers JP, Rogers JT, et al. Ultrasound-guided thoracentesis: is it a safer method? *Chest* 2003; 123:418–423.
21. Mayo PH, Goltz HR, Tafreshi M, et al. Safety of ultrasound-guided thoracentesis in patients receiving mechanical ventilation. *Chest* 2004; 125:1059–1062.
22. Barnes T, et al. Sonographically guided thoracentesis and rate of pneumothorax. *Journal of Clinical Ultrasound* 2005; 33(9):442-446.
23. Nazeer S, Dewbre H, Miller A. Ultrasound-assisted paracentesis performed by emergency physicians vs the traditional technique: a prospective, randomized study. *Am J Emer Med* 2005; 23(3):363-367.
24. Domingo-Triado V, et al. Ultrasound guidance for lateral midfemoral sciatic nerve block: a prospective, comparative, randomized study. *Anesth Analg* 2007; 104(5):1270-1274.

25. Liu SS, John RS. Modeling cost of ultrasound versus nerve stimulator guidance for nerve blocks with sensitivity analysis. *Reg Anesth Pain Med* 2010; 35(1):57-63.
26. Williams SR, et al. Ultrasound guidance speeds execution and improves the quality of supraclavicular block. *Anesth Analg* 2003; 97(5):1518-1523.
27. Schwemmer U, et al. Ultrasound-guided anaesthesia of the axillary brachial plexus: efficacy of multiple injection approach. *Ultraschall Med* 2005; 26(2):114-119.
28. Sandhu N, Manne J, Medabalmi P, Capan L. Sonographically guided infraclavicular brachial plexus blocks in adults. A retrospective analysis of 1,146 cases. *J Ultrasound Med* 2006; 25(12):1555-1561.
29. Orebaugh SL, Williams BA, Kentor ML. Ultrasound guidance reduces the time necessary for resident peripheral nerve blockade. *Reg Anesth Pain Med* 2007; 32(5):448-454.
30. Gray, AT. Ultrasound-guided regional anesthesia: current state of the art. *Anesthesiology* 2006; 104(2):368-373.
31. Marhofer P, Sitzwohl C, Greher M, Kapral S. Ultrasound guidance for infraclavicular brachial plexus anaesthesia in children. *Anaesthesia* 2004; 59(7):642-646.
32. Marhofer P, et al. Ultrasonographic guidance improves sensory block and onset time of three-in-one blocks. *Anesth Analg* 1997; 85(4):854-857.
33. Marhofer P, et al. Ultrasonographic guidance reduces the amount of local anesthetic for 3-in-1 blocks. *Reg Anesth Pain Med* 1998; 23(6):584-588.
34. Naredo E, et al. A randomized comparative study of short term response to blind injection versus sonographic-guided injection of local corticosteroids in patient with painful shoulder. *J Rheumatol* 2004; 31(2):308-314.
35. Sibbitt WL et al. Does sonographic needle guidance affect the clinical outcome of intraarticular injections? *J Rheumatol* 2009; 36(9):1892-1902.
36. Pourbagher MA, et al. Accuracy and outcome of sonographically guided intra-articular sodium hyaluronate injections in patients with osteoarthritis of the hip. *J Ultrasound Med* 2005; 24(10):1391-1395.
37. Cohen SP, et al. Comparison of fluoroscopically guided and blind corticosteroid injections for greater trochanteric pain syndrome: Multicentre randomised controlled trial. *BMJ* 2009; 338:b1088 doi: 10.1136/bmj.b1088.
38. Ojalehto M, Tikkakoski T, Rissanen T, Apaja-Sarkkinen M. Ultrasound-guided percutaneous thoracoabdominal biopsy. *Acta Radiologica* 2002; 43(2):152-158.
39. Deurloo EE, et al. Reduction in the number of sentinel lymph node procedures by preoperative ultrasonography of the axilla in breast cancer. *European Journal of Cancer* 2003; 39(8):1068-1073.
40. Van Rijk M, et al. Ultrasonography and fine-needle aspiration cytology can spare breast cancer patients unnecessary sentinel lymph node biopsy. *Annals of Surgical Oncology* 2005; 13(1):31-35.
41. Fine R, et al. Percutaneous removal of benign breast masses using a vacuum-assisted hand-held device with ultrasound guidance. *Am J Surg* 2002; 184(4):332-336.
42. National Institute for Clinical Excellence. Interventional Procedures Programme. Interventional procedures overview of image-guided biopsy of benign breast lesions. February 2005.
43. Can AS. Cost-effectiveness comparison between palpation- ultrasound-guided thyroid fine-needle aspiration biopsies. *BMJ Endocrine Disorders* 2009; 9:14.
44. Rasmussen LH, et al. Randomized trial comparing endovenous laser ablation of the great saphenous vein with high ligation and stripping in patients with varicose veins: short-term results. *J Vasc Surg* 2007; 46(2):308-315.
45. Bountouroglou DG, et al. Ultrasound-guided foam sclerotherapy combined with sapheno-femoral ligation compared to surgical treatment of varicose veins: early results of a randomised controlled trial. *Eur J Endovasc Surg* 2006; 31(1):93-100.
46. Lurie F, et al. Prospective randomized study of endovenous radiofrequency obliteration (closure procedure) versus ligation and stripping in a selected patient population (EVOLVEs Study). *J Vasc Surg* 2003; 38(2):207-214.
47. Van Rij AM, Chai J, Hill GB, Christie RA. Incidence of deep vein thrombosis after varicose vein surgery. *British Journal of Surgery* 2004; 91(12):1582-1585.
48. Mozes G, et al. Extension of saphenous thrombus into the femoral vein: A potential complication of new endovenous ablation techniques. *J Vasc Surg* 2005; 41(1):130-135.
49. O'Brien J, Caro J. Direct medical cost of managing deep vein thrombosis according to the occurrence of complications. *Pharmacoeconomics* 2002; 20(9):603-615.

Notes on Figures

Figure 1. Complications associated with IV catheterization are reduced with the use of ultrasound, and Estimated cost savings per 1,000 patients with ultrasound-guided IV catheterization.

Complication rates for hemothorax,¹⁴ pneumothorax,¹⁴ hematoma,¹⁴ failed insertion,¹⁶ arterial puncture,¹⁶ catheter misplacement,¹⁵ and catheter-associated bloodstream infection¹⁴ were obtained from published sources. Estimated cost savings per 1,000 patients were calculated by multiplying the difference in selected complication rates (where cost information was available) by the associated complication costs: pneumothorax (\$366.34, the midpoint of the reported range \$134.49-\$598.19);³ arterial puncture (\$57.35, converted from £40; <http://www.xe.com/ucc/>; 8/24/09);¹⁶ catheter misplacement (\$264.57, the midpoint of the reported range \$73.09-\$456.05);¹⁵ and catheter-associated bloodstream infection (\$11,971).¹⁷

Figure 2. Estimated cost of pneumothorax per 1,000 thoracentesis procedures.

The cost per pneumothorax episode was \$366.34, calculated as the midpoint of the range of \$134.49-\$598.19.³ Pneumothorax rates were 10.3% without ultrasound guidance and 4.9% using ultrasound guidance.²² Therefore, the estimated costs of pneumothorax per 1,000 thoracentesis procedures was \$17,950.66 with ultrasound guidance ($\$366 * 4.9\% * 1,000$) and \$37,733.02 without ultrasound guidance ($\$366 * 10.3\% * 1,000$).

Figure 3. Time to nerve block (minutes).

Total procedure time was calculated by summing performance time²⁶ and time to nerve block onset.³¹

Figure 4. Estimated cost of deep vein thrombosis per 1,000 varicose vein procedures, and Estimated number of deep vein thrombosis per 1,000 varicose vein procedures.

The cost per deep vein thrombosis (DVT) episode was \$10,537 when treated on an inpatient basis (midpoint of reported range of \$3,906-\$17,168), and \$2,882 when treated on an outpatient basis (midpoint of reported range of \$2,394-\$3,369).⁴⁹ DVT rates were 5.3% for surgical vein procedures,⁴⁷ and 1.5% (median of reported range 0.3%-2.7%) for ultrasound-guided EVLT/RF ablation.⁴⁸ Therefore, the estimated cost of DVT episodes per 1,000 surgical vein procedures was \$558,461 when treated in an inpatient setting ($5.3\% * \$10,537 * 1,000$) and \$152,746 when treated on an outpatient basis ($5.3\% * \$2,882 * 1,000$). In contrast, the estimated cost of a DVT episode per 1,000 ultrasound-guided EVLT/RF ablation vein procedures was \$158,055 when treated in an inpatient setting ($1.5\% * \$10,537 * 1,000$) and \$43,230 when treated on an outpatient basis ($1.5\% * \$2,882 * 1,000$).

©2011 General Electric Company – All rights reserved.

General Electric Company reserves the right to make changes in specifications and features shown herein, or discontinue the product described at any time without notice or obligation.

GE and GE Monogram are trademarks of General Electric Company.

GE Healthcare, a division of General Electric Company.

GE Healthcare
9900 Innovation Drive
Wauwatosa, WI 53226
U.S.A.
888 526 5144
www.gehealthcare.com



imagination at work